Journal of Wildlife Diseases, 33(2), 1997, pp. 220–225
© Wildlife Disease Association 1997

CONGENITAL DEFECTS IN NORTHERN ELEPHANT SEALS STRANDED ALONG THE CENTRAL CALIFORNIA COAST

J. G. Trupkiewicz,[1] F. M. D. Gulland,[2] and L. J. Lowenstine[1]

[1] Department of Pathology, Microbiology and Immunology, University of California at Davis, Davis, California 95616, USA

[2] The Marine Mammal Center, Golden Gate National Recreation Area, Marin Headlands, Sausalito, California 94965, USA

ABSTRACT: Eleven cases of congenital anomalies were identified in 210 (5%) juvenile northern elephant seals (*Mirounga angustirostris*) found stranded along the central California (USA) coast from 1 January 1988 to 31 December 1995. Seven individuals had mild-to-moderate hydrocephalus involving the lateral ventricles bilaterally, or the lateral and third ventricles. Two animals had severe cardiac anomalies: hypoplasia of the right ventricle with overriding aorta, and ventricular septal defect. Other anomalies included single cases of hydronephrosis, focal pulmonary dysplasia, and congenital epidermal angiomatosis. Common intercurrent disease processes were verminous pneumonia and arteritis, verminous enteritis and colitis, and splenic and hepatic hemosiderosis. The more severe anomalies were considered to be the cause of debilitation and stranding. Milder anomalies were found incidentally during routine gross necropsy and histopathologic examination.

Key words: Elephant seal, *Mirounga angustirostris*, hydrocephalus, hypoplastic right ventricle, overriding aorta, congenital anomalies.

INTRODUCTION

Congenital malformations have been frequently described in humans and domestic animals. Severe congenital defects are recognized in approximately 3% of human live births (Shephard, 1986). Spontaneous hydrocephalus has been documented in laboratory animals, non-human primates, cats, dogs, horses, sheep, and pigs with a prevalence of 0.1 to 7.7 per 1,000 live births (Szabo, 1989). Congenital malformations of the heart and great vessels occur with relatively low frequency in humans (six to eight cases per 1,000 births) (Schoen, 1994) and dogs (five per 1,000 births). However, higher prevalence is seen in mice (10 to 13 per 1,000 births) and rabbits (30 per 1,000 births) (Szabo, 1989), and breed and strain differences in prevalence of defects are evidence for a possible hereditary influence.

Spontaneous congenital defects are less frequently reported in free-ranging wildlife (Leipold, 1980). Congenital anomalies were cited as the cause of mortality in 1% of 1,820 northern fur seal (*Callorhinus ursinus*) pups on the Pribilof Islands, Alaska (USA), between 1986 and 1995 (T. R. Spraker, pers. comm.). Three cases of congenital deformity, out of 161 total pup mortalities, were listed without further explanation in a study of gray seal (*Halichoerus grypus*) mortality (Baker, 1984). Two cases of congenital defects in California sea lions (*Zalophus californianus*), aged 15 and 20 mo, respectively, were found in 53 animals from southern California (USA) beaches (Sweeney and Gilmartin, 1974). These were fusion of the splenic and hepatic capsules, and unilateral renal aplasia, respectively. Cleft palate, with associated ocular and facial deformities, was documented in a Kuril seal (*Phoca vitulina stejnegeri*) from the coast of Japan (Suzuki et al., 1992). Single cases of hydrocephalus in a northern elephant seal (*Mirounga angustirostris*) (Griner, 1983), and a penile malformation in a southern elephant seal (*Mirounga leonina*) (Csordas, 1966) have been reported. In this paper, we present eleven cases of congenital defects in free-ranging northern elephant seals found stranded along the coast of central California.

MATERIALS AND METHODS

Two hundred and ten juvenile northern elephant seals were examined by necropsy between 1 January 1988 and 31 December 1995.

TABLE 1. Congenital anomalies among 11 juvenile northern elephant seals (*Mirounga angustirostris*) stranded along the central California coast between 1 January 1988 and 31 December 1995.

Congenital anomaly	Number of cases	Age (mo) mean (range)	Sex (male/female)	Length (cm) mean (range)	Weight (kg) mean (range)
Hydrocephalus	7	4 (2–9)	6/1	137 (120–157)	60 (24–82)
Ventricular septal defect	1	3	1/0	138	24
Right ventricular hypoplasia and overriding aorta	1	3	1/0	130	53
Angiomatosis	1	2	1/0	157	82
Pulmonary dysplasia	1	11	1/0	138	62
Hydronephrosis	1	2	0/1	128	33
Polydactyly	1	4	1/0	132	43

Animals were found live stranded on beaches of central California (between 32°59′N, 121°30′W and 37°42′N, 123°05′W), and transported to The Marine Mammal Center, Sausalito, California. Sex, as determined by examination of external genital morphology (Reidman, 1990), weight, and total length were recorded for each animal. All animals were under 1 yr of age, and were aged in months based on the assumption that most elephant seals were born on Ano Nuevo, California, in January (LeBoeuf et al., 1972). Ten animals described here subsequently died or were euthanized due to continued deterioration of condition despite treatment. Euthanasia was accomplished by intravenous administration of 20 ml pentobarbitone (Pentobarbital solution, Anthony Products, Arcadia, California) into the extradural intravertebral sinus. One animal was released following successful rehabilitation.

After complete necropsy examination, representative samples of internal organs were immersion-fixed in 10% neutral buffered formalin for at least 72 hr. Fixed tissues were embedded in TissuePrep (Fisher Scientific, Fairlawn, New Jersey, USA), sectioned at 5μm, and stained with hematoxylin and eosin for examination by light microscopy (Luna, 1968).

FIGURE 1. Brain of a northern elephant seal. Hydrocephalus with marked distention of the lateral ventricles and atrophy of the overlying grey matter. Bar = 1 cm.

RESULTS

During the eight years from 1 January 1988 to 31 December 1995, 10 (5%) of 210 northern elephant seals examined at necropsy had significant abnormalities consistent with congenital anomalies. One additional animal with an obvious anomaly was successfully rehabilitated and released. Nine of the 11 animals were female, two male, and their ages varied between two and 11 months (Table 1).

Seven animals had gross evidence of hydrocephalus, with dilated lateral or third ventricles of the brain (Fig. 1), with obvious thinning of the overlying cortex. One animal had histologic evidence of a mild lymphoplasmocytic choroiditis. Two animals with hydrocephalus also had other congenital anomalies in other organs. One had a 1 cm high ventricular septal defect with partial coarction of the aorta at the level of the ductus arteriosus. Another had a 6 cm diameter, circumscribed, raised,

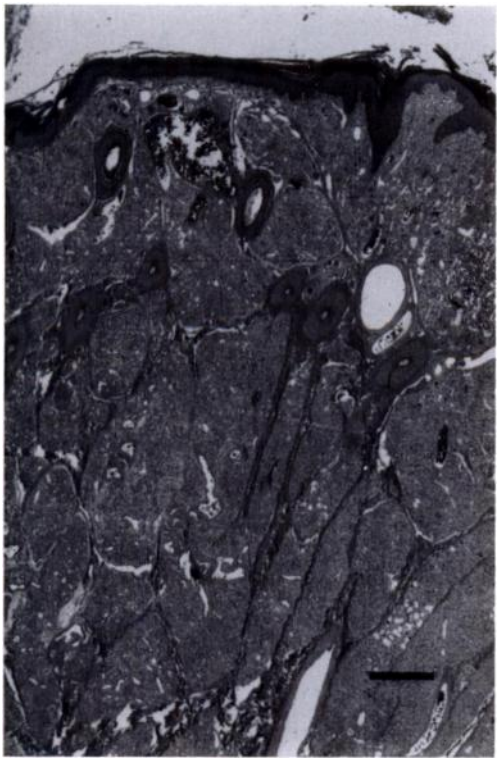

FIGURE 2. Skin of a northern elephant seal. Dermis expanded by numerous, occasionally blood-filled vascular spaces (angiomatosis). H&E. Bar = 500 μm.

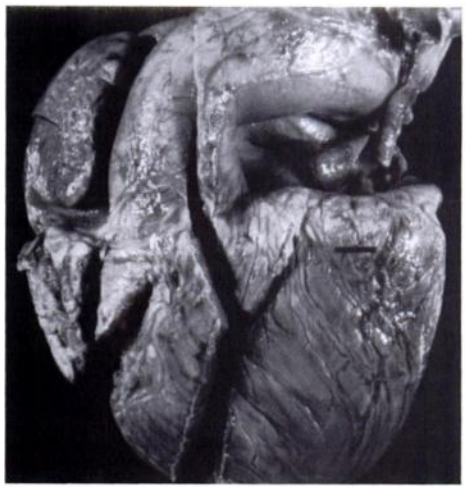

FIGURE 3. Heart of a northern elephant seal. Right ventricular hypoplasia and aplasia of pulmonary artery. Bar = 1 cm.

and ulcerated skin mass composed of numerous small arterioles and venules embedded in connective tissue, extending from the superficial dermis to the hypodermis, it was interpreted as a congenital angiomatosis (Fig. 2).

In one animal there was a large mass of vascular tissue within the anterior mediastinum and surrounding the heart. The heart was malformed, with severe dilatation of the right atrium, marked hypoplasia of the right ventricle, and aplasia of the main pulmonary artery. The outflow of the right ventricle was into an overriding aorta between the right and left ventricular outflow tracts. There were also small atrial and ventricular septal defects accounting for the outflow of the right atrium (Fig. 3).

Other anomalies seen included congenital hydronephrosis, focal pulmonary dysplasia, and polydactyly. In the animal with hydronephrosis, the left kidney was shrunken, and had cystic dilatation of the renal pelves of several reniculi. Cysts were lined by transitional epithelium and connective tissue. The affected reniculi had compression of the cortex and medulla, with clustering of glomeruli secondary to tubular loss. The pulmonary dysplasia was found incidentally on histopathologic examination, and was composed of a focal, well-demarcated region of pulmonary collapse, lacking discernable airways (Fig. 4). A single case of polydactyly was observed in a 4-mo-old animal which was rehabilitated and released.

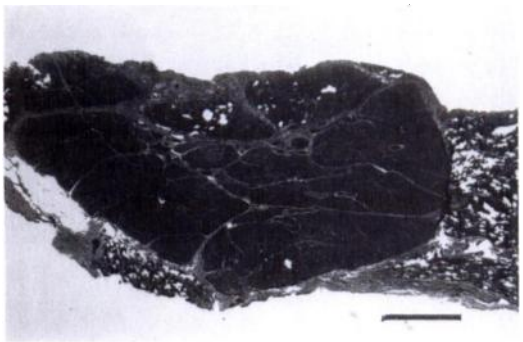

FIGURE 4. Lung of a northern elephant seal. Focal pulmonary dysplasia with atelectasis and agenesis of bronchioles. H&E. Bar = 1,000 μm.

DISCUSSION

The 5% prevalence of congenital anomalies in northern elephant seals examined at necropsy is higher than that reported in other surveys of marine mammal mortality. Our data were from animals stranded away from rookeries after weaning. As elephant seal pups dying on rookeries have not been examined, the true prevalence per 100 animals born may be considerably higher, as many animals with lethal congenital defects probably die during or shortly after birth.

Of the eleven cases of congenital anomalies described here, six were considered to be severe enough to contribute to the death of the animal. In addition to the cases described here, patent ductus arteriosus was observed in six elephant seals under 2 mo old (F. M. D. Gulland, unpubl.). Although this has been considered to be a congenital anomaly in pinnipeds by some authors (Leipold, 1980; Banish and Gilmartin, 1992), closure of this vessel may be delayed in marine mammals, as compared to terrestial species (Slijper, 1962).

Hydrocephalus was the most frequent congenital anomaly seen, and occurred predominantly in males. In one case, there was histologic evidence of a mild choroiditis. Although this lesion could be associated with obstruction of the cerebrospinal fluid outflow from the lateral ventricles, with subsequent pressure hydrocephalus formation, no loss of cerebral white matter was seen, which would be expected with cortical atrophy secondary to aquired hydrocephalus. In addition, severe choroiditis is frequently seen without hydrocephalus (Jubb and Huxtable, 1993); thus the hydrocephalus in this case probably was a congenital malformation.

The right ventricular hypoplasia and overriding aorta were striking lesions. The lumen of the right ventricle was markedly reduced, and its outflow was via an overriding aortic arch. Pulmonary circulation and oxygenation of blood was apparently via anomalous vessels within the pericardium and anterior mediastinum. No evidence for a normal pulmonary artery was found grossly. Perhaps these vessels arose as some aberrant development of the missing pulmonary circulation, or may have represented dilated collateral circulatory pathways.

There are many potential etiologies of congenital anomalies. There are various etiologies for congenital cerebral malformations, including hydrocephalus. Mercury (Murakami, 1972), ethylenethiourea (Khera and Iverson, 1980), thalidomide (Tanimura et al., 1971), irradiation (Senyszyn and Rugh, 1969), and hypovitaminosis A (Millen and Woollam, 1956) are known causes in humans or laboratory animals. Multiple cardiac defects have been induced in laboratory animals by prenatal exposure to radiation (Wilson et al., 1953), hypoxia (Ingalls et al., 1952), hypovitaminosis A (Wilson and Warkany, 1949), hypervitaminosis A (Fantel et al., 1977), azo dyes (Rosenkrantz et al., 1970), thalidomide (Khera, 1975), and corticosteroids (Nakayama et al., 1978). As yet, detailed toxicologic studies have not been performed on this population of elephant seals.

Viruses such as parvoviruses in cats, bluetongue and bovine virus diarrhea viruses in ruminants (Jubb and Huxtable, 1993), and influenza viruses in humans (Conover and Roessmann, 1990), hamsters (Takano et al., 1991) and non-human primates (London et al., 1975) can induce central nervous system malformations, while morbilliviruses can cause cardiac defects in humans (Schoen, 1994). No evidence of perinatal cerebral or cerebellar necrosis or inflammation was found in the cases presented here. However, viral isolation was not attempted, and the potential for an as-yet unrecognized infectious cause for these anomalies still exists.

Lack of genetic diversity may be a cause of high prevalence of congenital anomalies in the Florida panther (*Felis concolor*) (Roelke et al., 1993). However, exposure to environmental contaminants may also

be important (Facemire et al., 1995), as high numbers of congenital defects have not been documented in cheetahs (*Acinonyx jubatus*) despite their low level of genetic diversity (O'Brien et al., 1985). The northern elephant seal has a very low level of genetic diversity, possibly as a consequence of the near extinction of the population in the late 1800's following heavy hunting pressure (Bonnell and Selander, 1974). In contrast, harbor seals from California have a much higher degree of genetic diversity (Lehman et al., 1993). The prevalence of congenital anomalies in necropsied elephant seals stranded along the central California coast in this study (5%) is higher than the prevalence in similar aged harbor seals stranding in the same range and examined at post mortem (<0.1%) (F. M. D. Gulland, unpubl.). As weaned animals of these two species are in similar habitats and potentially exposed to similar contaminants and infectious agents, it is possible that genetic differences are important in explaining the different prevalences of congenital defects in these phocids.

In 1992, the elephant seal population was estimated at 125,000 (Stewart et al., 1992). Animals examined at post mortem thus represent only a small proportion of the overall population, most animals dying at sea. The prevalence of congenital defects in the total population may therefore be very different from that in stranded animals. However, we beleive that, based on our data, more detailed studies are needed to determine the relative roles of infectious agents, contaminants and genetics in causing congenital anomalies in northern elephant seals.

ACKNOWLEDGMENTS

We thank the volunteers and staff of TMMC for the rescue and rehabilitation of animals described here, the pathology residents from the University of California Veterinary Medicine Teaching Hospital for preliminary review of case materials; D. Fauquier, J. Roletto, Drs. K. Beckmen, L. Gage, J. Gerber, H. Feldman, S. Thornton and M. Tocidlowski for assistance in performing necropsies and Dr. T. Spraker for histologic examination of one case.

LITERATURE CITED

BAKER, J. R. 1984. Mortality and morbidity in grey seal pups (*Halichoerus grypus*). Studies on its causes, effects of environment, the nature and sources of infectious agents and the immunological status of pups. Journal of the Zoology 203: 23–48.

BANISH, L. D., AND W. G. GILMARTIN. 1992. Pathological findings in the Hawaiian monk seal. Journal of Wildlife Diseases 28: 428–434.

BONNELL, M. L., AND R. K. SELANDER. 1974. Elephant seals: Genetic variation and near extinction. Science 184: 908–909.

CONOVER, P. T., AND U. ROESSMANN. 1990. Malformational complex in an infant with intrauterine influenza viral infection. Archives of Pathology and Laboratory Medicine 114: 535–538.

CSORDAS, S. E. 1966. Congenital penis malformation in southern elephant seals (*Mirounga leonina*). Journal of Mammalogy 47: 731.

FACEMIRE, C. F., T. S. GROSS, AND L. J. GUILLETTE. 1995. Reproductive impairment in the Florida panther: Nature or nurture? Environmental Health Perspectives 103: 79–86.

FANTEL, A. G., T. H. SHEPARD, L. L. NEWELL-MORRIS, AND B. C. MOFFETT. 1977. Teratogenic effects of retinoic acid in pigtail monkeys (*Macaca nemestrina*). I. General features. Teratology 15: 65–71.

GRINER, L. A. 1983. Pathology of zoo animals. Zoological Society of San Diego, San Diego, California, p. 465.

INGALLS, T. H., F. J. CURLEY, AND R. A. PRINDLE. 1952. Experimental production of congenital anomalies. Timings and degree of anoxia as factors causing fetal deaths and congenital anomalies in the mouse. New England Journal of Medicine 247: 758–768.

JUBB, K. V. F., AND C. R. HUXTABLE. 1993. The nervous system. *In* Pathology of domestic animals, 4th ed., K. V. F. Kennedy and N. Palmer (eds.). Academic Press, San Diego, California, pp. 286–292.

KHERA, K. S. 1975. Fetal cardiovascular and other defects induced by thalidomide in cats. Teratology 11: 65–72.

———, AND F. IVERSON. 1980. Hydrocephalus induced by N-nitrosoethylenethiourea in the progeny of rats treated during gestation. Teratology 21: 367–370.

LEBOEUF, B. J., R. J. WHITING, AND R. F. GANTT. 1972. Perinatal behaviour of northern elephant seals and their young. Behaviour 43: 121–156.

LEHMAN, N., R. K. WAYNE, AND B. S. STEWART. 1993. Comparative levels of genetic variability in harbour seals and northern elephant seals as de-

termined by genetic fingerprinting. Symposium of the Zoological Society of London 66: 49–60.

LEIPOLD, H. W. 1980. Congenital defects in zoo and wild mammals: A review. *In* The comparative pathology of zoo animals, R. J. Montali and G. Migaki (eds.). Smithsonian Institution Press, Washington, D.C., pp. 457–470.

LONDON, W. T., D. A. FUCILLO, J. L. SEVER, AND S. G. KENT. 1975. Influenza virus as a teratogen in rhesus monkeys. Nature 255: 483–484.

LUNA, L. G. 1968. Manual of histologic staining methods of the Armed Forces Institute of Pathology, 3rd ed. McGraw Hill Company, New York, New York, 121 pp.

MILLEN, J. W., AND D. H. M. WOOLLAM. 1956. The effect of the duration of vitamin-A deficiency in the female rabbit upon the incidence of hydrocephalus in their young. Journal of Neurology and Neurosurgical Psychiatry 19: 17–20.

MURAKAMI, U. 1972. The effect of organic mercury on intrauterine life. *In* Drugs and fetal development, M. A. Klinberg, A. Abramovici, and J. Chemke (eds.). Plenum Press, New York, New York, pp. 301–336.

NAKAYAMA, T., R. HIRAYAMA, AND K. ESAKI. 1978. Effects of cortisone acetate in the beagle fetus. Teratology 18: 149A.

O'BRIEN, S. J., M. E. ROELKE, L. MARKER, A. NEWMAN, C. A. WINKLER, D. MELTZER, L. COLLY, J. F. EVERMANN, AND D. E. WILDT. 1985. Genetic basis for species vulnerability in the cheetah. Science 277: 1428–1434.

RIEDMAN, M. 1990. The pinnipeds: Seals, sea lions, and walruses. University of California Press, Berkeley, California, 439 pp.

ROELKE, M. E., J. S. MARTENSEN, AND S. J. O'BRIEN. 1993. The consequences of demographic reduction and genetic depletion in the endangered Florida panther. Current Biology 3: 340–350.

ROSENKRANTZ, J. G., F. P. LYNCH, AND W. W. FROST. 1970. Congenital anomalies in the pig: Teratogenic effects of tryptan blue. Journal of Pediatric Surgery 5: 232–237.

SCHOEN, F. J. 1994. The heart. *In* Pathologic basis of disease, 5th ed., R. S. Cotran, V. Kumar, and S. L. Robbins (eds.). W. B. Saunders, Philadelphia, Pennysylvania, pp. 571–579.

SENYSZYN, J. J., AND R. RUGH. 1969. Hydrocephaly following fetal X-irradiation. Radiology 93: 625–634.

SHEPARD, T. H. 1986. Human teratogenicity. Advances in Pediatrics 33: 225–268.

SLIJPER, E. J. 1962. Whales. Cornell University Press, Ithaca, New York, 511 pp.

STEWART, B. S., P. K. YOCHEM, H. R. HUBER, R. L. DELONG, R. J. JAMESON, W. SYDEMAN, S. G. ALLEN, AND B. J. LEBOEUF. 1992. History and status of the northern elephant seal population. *In* Elephant seals, B. J. Leboeuf and R. M. Laws (eds.). University of California Press, Berkeley, California, pp. 29–48.

SUZUKI, M., M. KISHIMOTO, S. HAYAMA, N. OHTAISHI, AND F. NAKANE. 1992. A case of cleft palate in a Kuril seal (*Phoca vitulina stejnegeri*) from Hokkaido, Japan. Journal of Wildlife Diseases 28: 490–493.

SWEENEY, J. C., AND W. G. GILMARTIN. 1974. Survey of diseases in free-living California sea lions. Journal of Wildlife Diseases 10: 370–376.

SZABO, K. T. 1989. Congenital malformations in laboratory and farm animals. Academic Press, San Diego, California, p. 709.

TAKANO, T., M. OHNO, T. YAMANO, AND M. SHIMIDA. 1991. Congenital hydrocephalus in suckling hamsters caused by transplacental infection with parainfluenza virus type 3. Brain and Development 13: 371–373.

TANIMURA, T., O. TANAKA, AND H. NISHIMURA. 1971. Effects of thalidomide and quinine dihydrochloride on Japanese and rhesus monkey embryos. Teratology 4: 247.

WILSON, J. G., AND J. WARKANY. 1949. Aortic arch and cardiac anomalies in the offspring of vitamin A deficient rats. American Journal of Anatomy 85: 113–156.

———, H. C. JORDAN, AND R. L. BRENT. 1953. Effects of irradiation on embryonic development. II. X-rays on the ninth day of gestation in the rat. American Journal of Anatomy 92: 153–188.

Received for publication 22 May 1996.